

Frequency of Fractures of the Locomotor Apparatus at the Burial Sites in the Area of the Castle in Mikulčice

JAKUB LIKOVSKÝ¹ – PETR VELEMÍNSKÝ² – LUMÍR POLÁČEK³ – JANA VELEMÍNSKÁ⁴

The goal of our study was to verify the frequency of injuries to the bones of the locomotor apparatus in a population group buried on the territory of the castle of the Great Moravian power centre at Mikulčice. The method of evaluation is based on the method of five segments, but we took the diaphyses of long bones to be a single segment, and we also evaluated the bones of the pectoral girdle of the upper extremities and the pelvis. In group of juvenile individuals no fracture was recorded on the studied bones. Adults represented a total of 531 individuals. In the whole group, a total of 59 fractures were recorded. There were 42 individuals with fractures - individuals with fractures represented 7.91% of the population. In the group of females were 8 fractures recorded in a total of 217 individuals – this represented 3.69% of individuals in the population of females; in the group of males a total of 31 individuals with a total of 43 fractures were uncovered – males with a fracture represented 10.83% of this group. The difference in the frequency of fractures between males and females was significant at the 1% level of significance. The frequency of fractures of the clavicle was statistically significantly higher compared to the other bones only in the case of the least affected femur and tibia. The prevalence of fractures of the radius was slightly higher than that described in studies focusing on British skeletal groups from the High Middle Ages. The overall higher frequency of fractures may be explained, for example, by the natural conditions of the locality.

Key words: palaeopathology – fracture – trauma – Great Moravia – Early Medieval

1. Introduction

1.1 Evidence of fractures in archaeological skeletal material

Signs of skeletal injuries and trauma represent – along with degenerative changes – the most frequently described pathological findings

in anthropological literature dedicated to past populations. Descriptions of the consequences of injuries and trauma may be found in skeletal findings from all periods – from the Palaeolithic Age to the Modern Age. Signs of injuries or trauma have been described practically in all anthropologically researched skeletal burial sites (see e.g. the summary of palaeopathological findings on the territory of Czechoslovakia HANÁKOVÁ/VYHNÁNEK 1981, the palaeopathological findings from the anthropological collection of the Institute of Archaeology in Prague (LIKOVSKÝ/STRÁNSKÁ/VELEMÍNSKÝ 2005). This also applies to the Great Moravian burial sites at Mikulčice (STLOUKAL/VYHNÁNEK 1976; VELEMÍNSKÝ 2000; VELEMÍNSKÝ et al. 2005). Most often, though, this only involved

1 Department of the Archaeology of Landscape and Archaeobiology, Institute of Archaeology, Academy of Sciences of the Czech Republic, v.v.i., Prague, CZ, likovsky@arup.cas.cz

2 Department of Anthropology, National Museum, Prague.

3 Institute of Archaeology, Academy of Sciences of the Czech Republic, v.v.i., Brno, CZ

4 Department of Anthropology and Human Genetic, Faculty of Science, Faculty of Sciences, Charles University, Prague, CZ.

case reports, which were not correlated with the number of individuals and the state of preservation of the skeletons or individual bones.

The localisation of injuries on the skeleton may hint at the living conditions and lifestyle, the type of work conducted, as well as the mechanism of injury itself. Differences may be expected between the sexes, between individuals of various social rank, between populations of various eras and cultures.

Post-traumatic states may also give a clue as to the level of “medical care” in the past. The quality of the treatment of injuries may be evaluated according to the manner, in which the fracture has healed, with a smaller or greater dislocation of the fragments given by the method of fixation. Or according to the frequency, manner of execution and percentage of healing of true surgical procedures, conducted most often after trauma, and exemplified on the skeletons in the form of amputations of extremities or post-traumatic trepanation of skulls with the extraction of bone fragments.

1.2 Classification of trauma

Traumatic changes of the skeleton may be assessed from several aspects – this has been repeatedly described in both medical and anthropological literature; especially in textbooks (e.g. STEINBOCK 1976; AUFDERHEIDE/RODRÍGUEZ-MARTÍN 1998; VYHNÁNEK 1999; HORÁČKOVÁ/STROUHAL/VARGOVÁ 2004; ROBERTS/MANCHESTER 2007). According to the physiological state of the bone, fractures are classified as traumatic, induced by force acting on healthy bone and exceeding its mechanical properties of pressure, torsion or flexure (this group includes most of the accidental and deliberate injuries) and pathological, induced by normal stress on a bone weakened by a pathological process (most often associated with metabolic disease – osteoporosis, or malignant lesions).

From the aspect of trauma occurrence, we differentiate whether the cause was an accident, or if the injury was deliberate. Accidental injuries occur during routine human activities – careless handling of instruments and tools, falls. Deliberate

(intentional) injuries mainly include those caused by weapons – slashes, stab wounds (e.g. STLOUKAL/VYHNÁNEK 1976; VYHNÁNEK 1999), wounds caused by a blunt object (LIKOVSKÝ/DRDA 2003). Slash wounds are most often found on skulls, but may also appear on the diaphyses of long bones – the course of the line here corresponds to the horizontal position of the bone during the injury and is often attributed to injuries incurred by riders or horsemen (STLOUKAL/VYHNÁNEK 1976).

A very peculiar category is represented by so-called stress fractures that are induced by long-term stress and strain, and are most frequently located in the area of the metatarsi – these mainly involve small fissures, which are often difficult to detect (e.g. KOUDELA et al. 2002; HORÁČKOVÁ/STROUHAL/VARGOVÁ 2004).

According to the extent of bone damage, we divide fractures into complete and partial – incomplete fractures involve only the partial fracture of the bone or the formation of cracks. The most frequently used classification of fractures involves their division according to the course of the fracture line and differentiates between transverse, oblique, longitudinal, spiral and splintered fractures. Transverse fractures are caused by a relatively small force acting on a small surface and the resulting fracture line is perpendicular to the longitudinal axis of the bone. The oblique fracture line is most frequently caused by direct force acting at an angle or rotationally. In contrast to oblique fractures, spiral fractures rotate around the bone’s longitudinal axis (e.g. BEDNÁŘ et al. 1984; LOVELL 1997).

1.3 Injuries of the locomotor apparatus

Injuries of the locomotor apparatus may occur randomly, by accident, but these injuries may also be intentional or deliberate (see the aforementioned injuries of riders), or they may occur in self-defence – this is mainly associated with the bones of the forearm – so-called reflexive fracture or parry fracture (VYHNÁNEK 1999).

The following brief overview of the most frequent fractures and the mechanism of their development shows that in a number of cases it

is difficult to differentiate between accidental and deliberate injuries.

1.3.1 Fractures of the pectoral girdle bones and the long bones of the upper extremity.

Fractures of the clavicle are considered to be frequent and usually occur indirectly by falling on an extended upper extremity or due to a direct impact on the area of the shoulder. These fractures occur most frequently (approx. 76%) in the middle section or (approx. 20%) in the lateral third of the diaphysis (VIŠŇA/HOCH 2004; POKORNÝ et al. 2002). Their incidence is said to be higher in males and more often the left clavicle is involved (STLOUKAL/VYHNÁNEK 1976). Injuries of the scapula most often occur concomitantly with fractures of the humerus, clavicle or chest.

The humerus may be fractured in the region of its proximal end – fractures of the so-called surgical neck occur during falls and osteoporosis is usually a predisposing factor. In the region of the diaphysis, fractures occur due to direct intense force (a fall or violent strike on the arm). In the region of the distal epiphysis, fractures are most often localised supra-condylarly, or they are Y-shaped (during falls on a dorsally flexed arm or on the area of the elbow – when the olecranon ulnae is injured concurrently), most often in the supra-condylar area.

Besides fractures of the clavicle, fractures of the bones of the forearm are considered to be the second most frequent localisation of fractures. Their classification (Colles, Smith, Barton's, Monteggia, Galeazzi fractures etc.) is based on the mechanism of injury. In fractures of both bones of the forearm (due to a fall on the extended arm or due to a direct strike), the fracture line usually runs in the middle of the diaphysis. Isolated fractures of the ulna usually occur during the defensive holding out of the forearm.

1.3.2 Fractures of the pelvis and the bones of the lower extremities.

Fractures of the pelvis that usually occur by falling directly on the pelvis or indirectly by transfer of force during falls on both feet from a height are – perhaps with the exception of partial

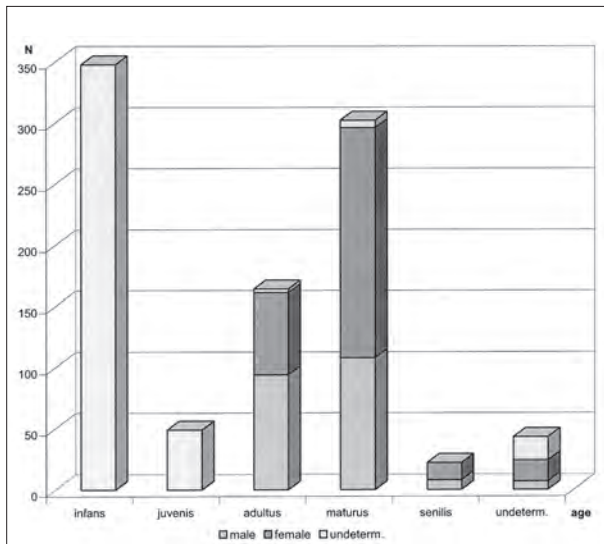
fractures involving the pelvic bone projections – serious, life-threatening injuries, often associated with other trauma. Practically, all the pelvic bones may be broken (the ilium, ischium and pubis). Apart from this, fractures in the area of the hip joint socket due to the transfer of force across the femoral head. The most frequent fractures are those involving the rami of the pubic bone (see e.g. HOFFA 1896).

Fractures of the femur most often occur in the area of the proximal end – the area of the neck and trochanters. These fractures are typical for skeletons affected by osteoporosis and their rising numbers currently represent a worldwide problem (e.g. ŠTĚPÁN 1990) (see LIKOVSKÝ/VELEMÍNSKÝ/ZIKÁN this book, pp. 223-234). It is reported that fractures of the per-trochanteric area are so typical that they can be distinguished in skeletal material even in cases where healing failed to occur (VYHNÁNEK 1999). Fractures of the femoral diaphysis, if bone continuity is interrupted, may be extremely dislocated due to the pull of muscles and may heal with a significant callus – they thus rank among the most conspicuous pathologies on the skeleton. Fractures of the femoral distal epiphysis occur due to a fall or strike on the flexed knee. In such cases, the condylar or supra-condylar area is injured.

Fractures of the tibia are most frequently diaphysar, and they occur with nearly the same frequency in both sexes (VYHNÁNEK 1999). 20% of cases involve open fractures, which may easily lead to infectious complications of the injury. A depressive fracture of the lateral condyle is characteristic for the proximal epiphysis of the tibia. Fractures of the diaphysis – most often spiral – are usually associated with a fracture of the neck of the fibula, for which the most characteristic fracture is that in the area of the distal end-lateral ankle (malleolus).

1.4 Diagnostics of fractures in archaeological skeletal material

The limiting factor of the evaluation of archaeological skeletal remains is, on one hand, the completeness of the individual skeletons,



Graph 1. Basic demographic structure of the Mikulčice castle population.

and on the other the state of preservation of the bones in question. Naturally, the completeness and preservation of skeletons also dictate the possibility of identifying and evaluating traumatic changes.

The basic problem of evaluating injuries is the ability to distinguish the unhealed post-traumatic state from post-mortem damage to the bone. With the exception of those cases, where there is an unequivocal mark of the instrument (weapon or sharp object) that caused the injury, post-mortem damage and (non)deliberate force cannot be distinguished with certainty. Even in those cases where the course of the fracture line corresponds to a type of fracture known in clinical practice and where it would be possible – if an old fracture line is uncovered – to consider a fracture incurred peri-mortem (STLOUKAL/VYHNÁNEK 1976), a certain degree of doubt remains.

Several authors have studied the possibilities of differentiating unhealed fractures from damage (e.g. MAPLES 1986). Nonetheless, even the study of recent skeletal material has shown that not even microscopy methods can demonstrate a fracture less than two weeks old (MANN/MURPHY 1990).

Therefore, accidental, unintentional injuries can be studied in palaeopathology only if the fracture healed – a callus developed and the shape or

axis of the bone changed. A fracture usually heals completely within 3–4 months from the injury (BEDNÁŘ et al. 1984); if no complications occur – for example, infection at the site of injury, inadequate fixation of the fragments, necrosis. X-rays help in the correct assessment of the character of a fracture (see e.g. VYHNÁNEK 1999).

The frequency of fractures in the population has been studied by several authors in the past decades, and various methods of evaluation have been devised (for an overview see ROBERTS/MANCHESTER 2007). Stress is placed on the relationship between the fractures and the true number of individual preserved bones (e.g. MÜLLER et al. 1990; GRAUER/ROBERTS 1996). Certain methods are capable of working with fragmented material (JUDD 2002).

2. Materials

2.1 Selection of the population group

For our research, we have selected burial sites located within Mikulčice castle itself, where archaeologists presume the socially more powerful ranks of Great Moravian society are buried, i.e. including the burial of males – “warriors” (e.g. POULÍK 1975). These burial sites include the one beside the second Mikulčice church (252 graves) and the one next to the three-nave basilica the largest church of the Mikulčice-castle (569 graves).

In our selection, from a demographic aspect, we also drew from the conclusions of STLOUKAL (1963, 1967) with a delimitation of both burial sites according to the extent known in the 1950s – i.e. burial site 1 (IInd church) and burial site 2 (IIIrd church). We then extended the results acquired (LIKOVSKÝ et al. in print) to include those of later explorations of a section of the necropolises (POLÁČEK/MAREK 2005). In total, the burial sites around the IInd and IIIrd Mikulčice church now include 950 graves (Fig. 1a, 1b). From these, 928 skeletons or parts of skeletons, which could be marked as the remains of individuals, were available for our evaluation. The remaining bones consisted of grave admixtures.

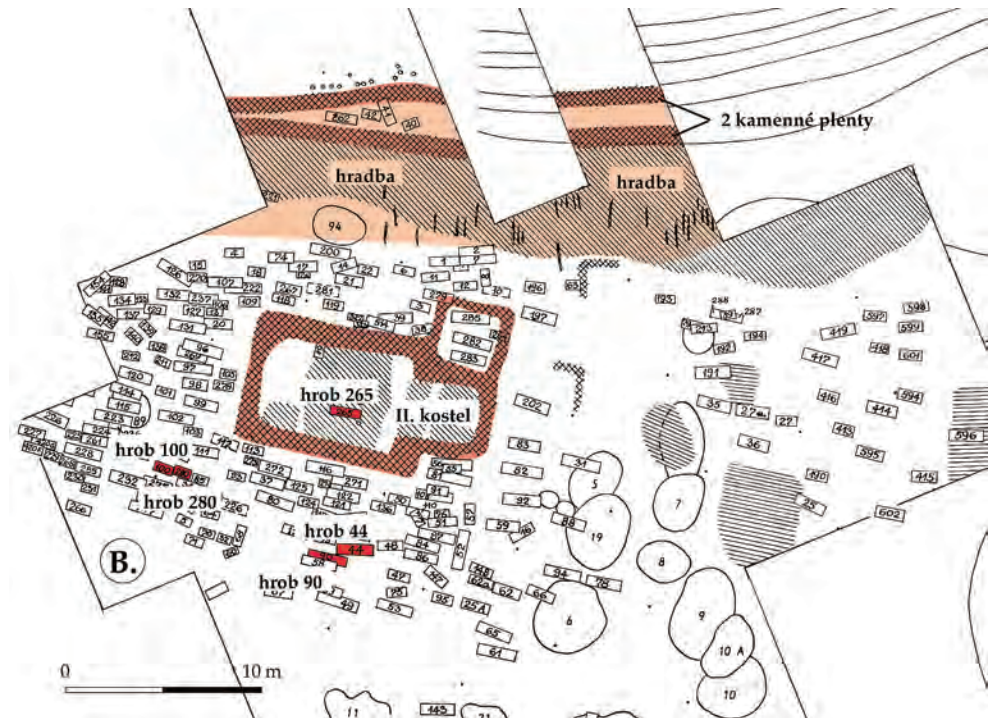


Fig. 1a. Mikulčice-castle. Burial-grounds- in the surrounding of the IInd church.

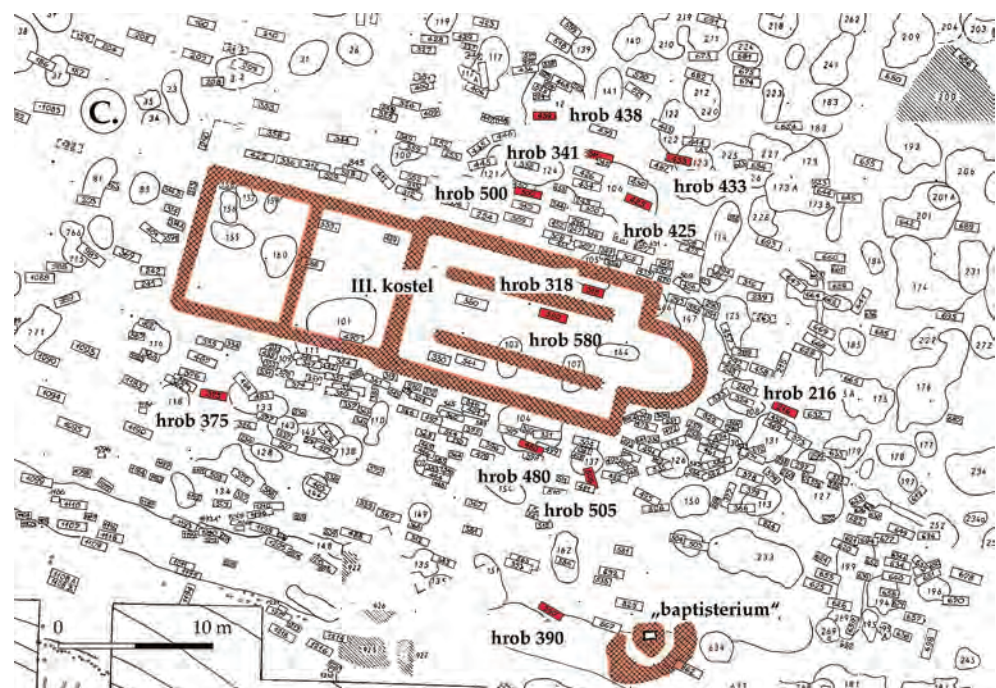


Fig. 1b. Mikulčice-castle. Burial-grounds in the surrounding of the IIIrd church.

2.2 Basic demographic data

A total of 928 individuals originate from both the evaluated burial sites, i.e. from the whole locality of Mikulčice castle. We excluded from our research the skeletons of children, which represent a total of 348 individuals. We evaluated a total of 49 skeletons of juvenile individuals

and 531 of adults. In five cases, the material was designated as grave admixture.

Our group of evaluated adults included a total of 217 female, 286 males and 28 individuals of undetermined sex. From the aspect of age, the adult group contained 163 individuals of the adultus age group (Ad. I-II, 20-39 years),

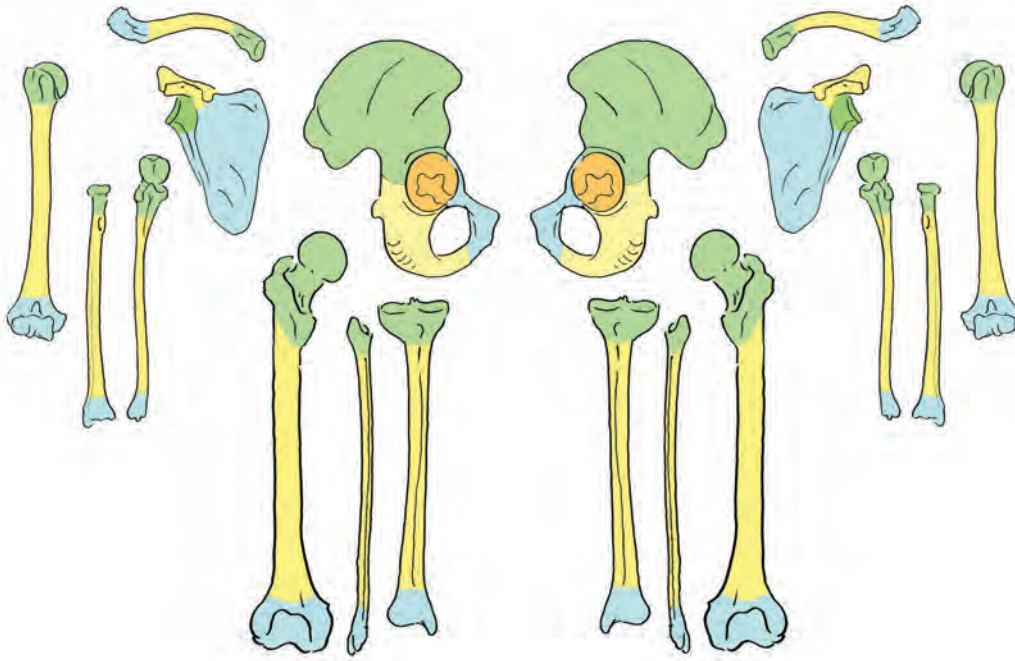


Fig. 2. Definition of evaluated bone segments of locomotory apparatus

302 individuals of the matusus age group (Mat. I-II, 40-59 years) and 22 individuals of the senilis age group (Sen., over 60 years). There were 94 adult females and 67 adult males. The matusus group included 108 females and 188 males, and the senilis group 8 females and 14 males. The sex could not be determined in the remaining individuals in each category (Graph 1).

3. Methods

3.1 Diagnostics of bone fractures

All the bones were evaluated aspectively, and their degree of preservation (or completeness according to the selected division into segments – see below) was recorded, as was the eventual presence of traumatic changes: alterations of the bone axis, irregularities of the bone surface, the presence of pseudo-joints etc. Although post-traumatic changes are quite apparent already on visual inspection, X-rays of all suspected traumatic lesions were made and assessed, in order to verify the presence and to determine the extent of the given lesions (the course of the fracture line, the

extent of reparative changes, eventual complications – see STLOUKAL/VYHNÁNEK 1976). Photodocumentation was made concurrently.

During the evaluation itself, we based our procedures on publications dedicated to traumatology or orthopaedics, including works deemed historical today (e.g. HOFFA 1896) and on paleopathological literature (e.g. STEINBOCK 1976; AUFDERHEIDE/RODRÍGUEZ-MARTÍN 1998; ROBERTS/MANCHESTER 2007).

3.2 Population evaluation of fractures of the post-cranial skeleton

We approached the issue of evaluating the frequency of traumatic lesions within the selected population not only in relation to the number of individuals involved, but mainly to the state of preservation of individual bones and their sections. In view of the size of the population studied and the degree of preservation of the material, we based ourselves mainly on the method described by JUDD (2002), which was devised for the evaluation of fragmented skeletal material. We simplified the method of five segments in view of the degree of preservation of the material studied as

Table 1. The incidence of fractures in the evaluated population, number of bones and segments.

N = number of evaluated cases; M = male, F = female, ? = undetermined, adm = admixture

	F+M+?	F	M	?
n of individuals	531	217	286	28
individuals with fracture	42	8	31	3
% of individuals with fracture	7.91	3.69	10.83	10.71
n of bone segments	14346	5906	8131	309
n of fractures	54	8	43	3
% of segment fracture	0.38	0.14	0.53	0.97
n of really whole bones	3362	1343	1947	72
n of „whole“ bones calculated by extrapolation	459	224	217	18
% of fractures of all whole bones	1.41	0.51	1.99	3.33

follows: we considered the diaphyses of long bones to be a single segment; in the case of the scapula we evaluated independently the cavitas glenoidalis region, acromial and coracoid processes, and the surface of the scapula itself. We divided the pelvis anatomically into the os illii, os ischii and os pubis, with the acetabulum evaluated as an independent unit because of the possibility of indirect trauma (Fig. 2). The demarcation of the epiphyses of long bones corresponded to the older, practical method of squares (MÜLLER et al. 1990).

The division of bones into segments enabled us not only to evaluate truly preserved complete bones, but also to increase the number of individual bones by extrapolating segments preserved independently within the selected groups (non-adults, adult females, adult males and adults of undetermined sex).

Fisher's exact test of the four-field contingency table (DIXON/MASSEY 1969) at a 5% and 1% level of significance was used to mutually compare the differences in the incidence of trauma in the individual groups evaluated.

4. Results

4.1 Frequency of fractures in the population

The incidence of fractures was evaluated in relation to the individuals affected, the individual bones, as well as the localisation of the traumatic lesions themselves on the bones divided

into three independently studied segments, and in the case of the pelvis into four independently studied segments.

From the aspect of fracture incidence, the bones of 49 individuals included in the juvenis group (15-19 years) were evaluated. In this group, 216 individual complete bones as well as incomplete bones were evaluated – the total number of segments evaluated (complete bones and fragments) was 839. No fracture was recorded on the studied bones in the juvenis group.

Adults represented a total of 531 individuals – a total of 3362 complete bones were examined, with the help of segments this number was increased by a further 452 “complete” bones using extrapolation (total of 3814 bones); a total of 14346 individual segments were evaluated. This number is incremented by additional findings designated as admixtures – this involved a total of 21 segments, including six complete bones (total of 14367 segments).

A total of 54 fractures were recorded in the whole group of adult individuals, the number of individuals with a fracture was 42 – individuals with a fracture represented 7.91% of the population. If we add the bones designated as admixtures, the number of fractures uncovered increases to 59. Thus, from the total 3814 evaluated bones (including those calculated by extrapolation), bones with a fracture represent 1.54%. From the total of 14367 evaluated segments, fractures represent 0.41%.

Table 2. The bones, evaluated bone segments and observed fractures of the pectoral girdle and long bones of the upper extremity.

		clavicle						scapula					
		dx			sin			dx			sin		
		sternal	diaphysis	acromial	sternal	diaphysis	acromial	glen	proc	angulus	glen	proc	angulus
F	n of bone segments	109	116	98	108	115	94	115	49	17	115	49	18
	n of fractures	-	-	-	-	1	-	-	-	-	-	-	-
	% of segment fracture	-	-	-	-	0.87	-	-	-	-	-	-	-
	n of realy whole bones		87			82			16			18	
	n of „whole“ bones calculated by extrapolation		11			12			1			-	
	% of fractures of all whole bones		-			1.06			-			-	
M	n of bone segments	162	164	143	153	154	132	156	83	35	145	73	28
	n of fractures	-	-	2	-	3	4	1	1	1	2	-	-
	% of segment fracture	-	-	1.4	-	1.95	3.03	0.64	1.2	2.86	1.38	-	-
	n of realy whole bones		137			128			33			27	
	n of „whole“ bones calculated by extrapolation		6			4			2			1	
	% of fractures of all whole bones		1.4			5.3			8.75			7.14	
?	n of bone segments	6	6	6	5	6	6	6	3	1	6	1	2
	n of fractures	-	-	-	-	-	1	-	-	-	-	-	-
	n of realy whole bones		6			5			1			1	
	n of „whole“ bones calculated by extrapolation		-			-			-			-	
ant	n of bone segments	1	1	1	-	-	-	-	-	-	-	-	-
	n of fractures	-	-	1	-	-	-	-	-	-	-	-	-
	n of realy whole bones		1			-			-			-	
F + M + ? + ant	n of bone segments	278	287	248	266	275	232	277	135	53	266	123	48
	n of fractures	-	-	3	-	4	5	1	1	1	2	-	-
	% of segment fracture	-	-	1.21	-	1.46	2.11	0.36	0.74	1.89	0.75	-	-
	n of realy whole bones		231			215			50			46	
	n of „whole“ bones calculated by extrapolation		17			17			3			2	
	% of fractures of all whole bones		1.21			3.88			5.66			4.17	

In the group of females (total of 217 individuals), there were eight fractures in a total of eight individuals. In the population of females, this represents 3.69% individuals with fractures. From

the aspect of age, six cases involved females of the maturus category and two cases was recorded in the adultus age category.

humerus						radius						ulna					
dx			sin			dx			sin			dx			sin		
proximal	diaphysis	distal	proximal	diaphysis	distal	proximal	diaphysis	distal	proximal	diaphysis	distal	proximal	diaphysis	distal	proximal	diaphysis	distal
99	151	103	103	154	103	105	122	108	88	114	100	101	113	82	98	107	79
-	-	-	-	-	-	-	-	-	-	1	-	-	3	-	-	-	-
-	-	-	-	-	-	-	-	-	-	0.88	-	-	2,65	-	-	-	-
	75			77			88			76			69			68	
	28			26			17			12			13			11	
	-			-			-			1.14			3.66			-	
136	199	158	134	189	142	143	171	159	136	167	157	154	158	126	148	160	120
1	1	1	2	2	-	-	2	1	-	1	3	-	1	-	-	3	1
0.74	0.5	0.63	1.49	1.06	-	-	1.17	0.68	-	0.6	1.91	-	0.63	-	-	1.88	0.83
	125			114			125			123			113			105	
	11			20			18			13			13			15	
	2.21			2.98			2.09			2.94			0.79			3.33	
6	7	5	5	7	6	5	6	5	5	5	6	5	6	5	4	6	6
-	-	-	-	-	-	-	-	-	-	1	-	-	-	-	-	1	-
	5			5			5			4			5			4	
	-			-			-			1			-			-	
-	-	-	-	-	-	-	-	-	-	-	-	-	-	-	1	1	-
-	-	-	-	-	-	-	-	-	-	-	-	-	-	-	-	1	-
	-			-			-			-			-			-	
241	357	266	242	350	251	253	299	272	229	286	263	260	277	213	251	274	205
1	1	1	2	2	-	-	2	1	-	3	3	-	4	-	-	5	1
0.41	0.28	0.38	0.82	0.57	-	-	0.67	0.36	-	1.04	1.14	-	1.76	-	-	1.82	0.49
	205			196			218			203			187			177	
	36			46			35			26			26			28	
	1.24			1.65			1.19			2.62			1.88			2.93	

In the group of males (286 individuals), a total of 43 fractures were uncovered in 31 individuals – several cases involved multiple injuries (see below). Males with fractures in this group thus represent

10.83%. From the aspect of the age reached, fractures were recorded in two males from the adultus category, in 28 males from the maturus category and in two individuals from the senilis group.

Table 3. The bones, evaluated bone fragments and observed fractures of the pelvic bone and long bones of the lower extremity.

		pelvic bone							
		dx				sin			
		acetabulum	ilium	pubis	ischium	acetabulum	ilium	pubis	ilium
F	n of bone segments	123	98	70	72	123	96	71	77
	n of fractures	-	-	-	-	-	-	-	-
	% of segment fracture	-	-	-	-	-	-	-	-
	n of really whole bones		56			57			
	n of „whole“ bones calculated by extrapolation		14			14			
	% of fractures of all whole bones		-			-			
M	n of bone segments	181	132	120	119	179	125	125	118
	n of fractures	-	-	1	-	-	-	2	-
	% of segment fracture	-	-	0.83	-	-	-	1.6	-
	n of really whole bones		97			97			
	n of „whole“ bones calculated by extrapolation		22			28			
	% of fractures of all whole bones		0.84			1.69			
?	n of bone segments	5	5	5	4	5	6	3	3
	n of fractures	-	-	-	-	-	-	-	-
	n of really whole bones		4			3			
	n of „whole“ bones calculated by extrapolation		-			-			
ant	n of bone segments	-	-	-	-	-	-	1	-
	n of fractures	-	-	-	-	-	-	-	-
	n of really whole bones		-			-			
F + M + + ? + ant	n of bone segments	309	235	195	195	307	227	200	198
	n of fractures	-	-	1	-	-	-	2	-
	% of segment fracture	-	-	0.51	-	-	-	1	-
	n of really whole bones		157			157			
	n of „whole“ bones calculated by extrapolation		38			43			
	% of fractures of all whole bones		0.51			1.0169			

The difference in the frequency of fractures between males and females – regardless whether we based our calculations on the number of individuals with fractures or on the total number of fractures uncovered – is significant at the 1% level of significance.

The group of adult individuals with no possibility of determining sex is the smallest – only 28 individuals. In this group, three fractures were recorded in three individuals.

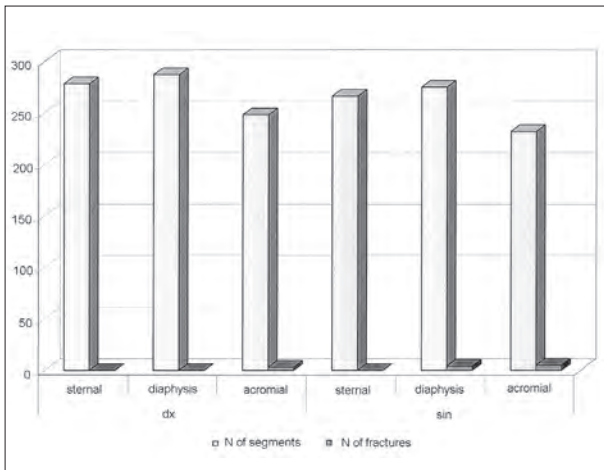
Cases designated as admixtures represent a special group (see Section 5.2). Only eight bones

femur						tibia						fibula					
dx			sin			dx			sin			dx			sin		
proximal	diaphysis	distal	proximal	diaphysis	distal	proximal	diaphysis	distal	proximal	diaphysis	distal	proximal	diaphysis	distal	proximal	diaphysis	distal
141	177	146	142	173	150	131	156	134	125	154	142	48	89	89	52	97	97
-	-	-	1	-	-	-	-	-	1	-	-	-	-	-	1	-	-
-	-	-	0.7	-	-	-	-	-	0.8	-	-	-	-	-	1.92	-	-
	126			130			117			116			39			46	
	15			12			14			9			9			6	
	-			0.7			-			0.8			-			1,92	
188	228	185	192	221	178	158	204	178	157	201	179	54	111	117	55	119	122
-	1	-	-	-	-	-	-	1	-	-	-	-	1	-	1	2	1
-	0.44	-	-	-	-	-	-	0.56	-	-	-	-	0.9	-	1.81	1.68	0.82
	167			166			147			142			52			49	
	18			12			11			15			2			6	
	0.53			-			0.63			-			1.85			7.27	
5	12	7	7	15	6	4	9	10	4	6	8	4	5	6	3	4	4
-	-	-	-	-	-	-	-	-	-	-	-	-	-	-	-	-	-
	5			5			4			3			4			3	
	-			1			-			1			-			-	
1	1	1	1	1	1	1	1	1	1	1	1	1	1	1	-	-	-
1	-	-	-	-	-	-	1	-	-	-	-	-	1	-	-	-	-
	1			1			1			1			1			-	
335	418	339	342	410	335	294	370	323	287	362	330	107	206	213	110	220	223
1	1	-	1	-	-	-	1	1	1	-	-	-	2	-	2	2	1
0.3	0.24	-	0.29	-	-	-	0.19	0.31	0.35	-	-	-	0.97	-	1.81	0.91	0.45
	299			302			269			262			96			98	
	36			33			18			25			11			12	
	0.6			0.3			0.34			0.35			1.87			4.55	

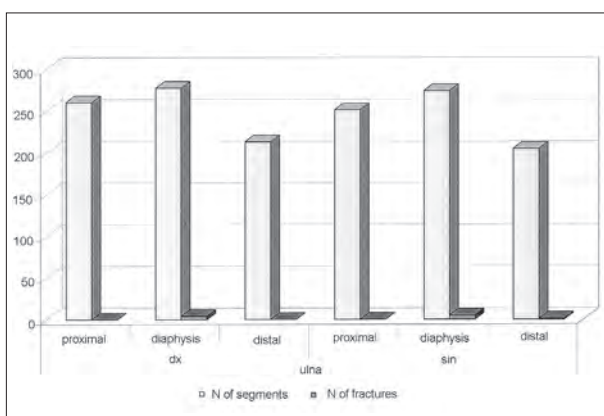
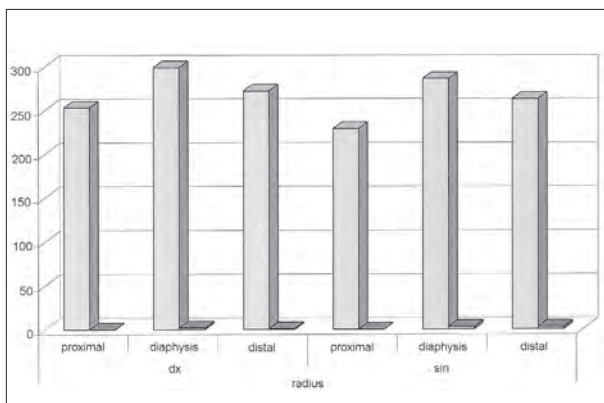
were evaluated, of which six were complete, and fractures were uncovered in five cases.

An overview of the incidence of fractures in the evaluated population, including their relation to the number of segments evaluated is presented in Table 1.

Multiple fractures were noted in several individuals, and in some it is highly probable that they occurred concurrently. In one case, four fractures were discovered on a single skeleton (scapula, humerus, radius, fibula), in another three were found (clavicle, humerus, tibia).



Graph 2. The frequency of clavicle's fractures in relation to localisation of injury.



Graph 3. The frequency of forearm bones fractures in relation to localisation of injury.

The remaining cases involved fractures of two bones (for details of individual findings see Section 4.3).

4.2 Localisation of injuries

4.2.1 Incidence and frequency of fractures according to the individual evaluated bones

4.2.1.1 Fractures of the pectoral girdle bones and the upper limb's long bones

Fractures of the clavicle were recorded in the group of females in only one case; in the group of males, they were recorded in a total of nine cases (for the number of bones and segments see Table 2) – the difference between the sexes is not significant. In two cases, the fractures were localised on the right (on the acromial end), eight cases were localised on the left (4 x fracture of the diaphysis, 4 x traumatic changes of the acromial end) – the difference in laterality is also not significant (Graph 2).

Traumatic changes of the scapula were recorded only in males, namely in five cases. A total of three cases involved the region of the glenoid cavity, one case involved the acromial process and another of the margo lateralis. In view of the poor state of preservation, it was possible to evaluate only the differences in numbers in the case of the cavitas glenoidalis, and not in relation to complete bones: three fractures from a total of 301 evaluated cavitas glenoidalis of males and 0 cases in 230 cavitas glenoidalis of females do not represent a statistically significant difference.

Even fractures of the humerus were uncovered only in males, namely in seven cases. Three fractures were recorded in the region of the proximal epiphysis, three fractures involved the diaphysis and one trauma was noted in the region of distal epiphysis. The difference in laterality, 3:4, is not statistically significant. The difference in the incidence of fractures in males compared to the unaffected females (for the number of bones and fragments see Table 2) is significant at the 5% level of significance.

Fractures of the forearm were uncovered in both sexes. Fractures of the radius in males were recorded in seven cases – three on the right, four on the left. On the right, two were located in

the region of the diaphysis and one in the distal epiphysis; on the left, one was located in the region of the diaphysis and three in the distal epiphysis. In females, only a single fracture of the radius – on the left, in the region of the diaphysis – was recorded. The differences in laterality are not significant. The inter-sexual difference is also not significant. Fractures of the ulna were recorded in females in three cases (on the right), and in males in five cases (one on the right, four on the left). Neither the difference between the right and left side, nor the difference between the sexes are statistically significant (Graph 3; for number of bones and segments see table 2).

4.2.1.2 *Fractures of the pelvis and the lower limb's long bones*

Fractures of the pelvic bones were discovered only in males, and from the aspect of localisation only in the region of the pubic bone rami. These findings involved two cases of fractures, in one case the lesion was bilateral. Although no fracture of the pelvic area was discovered in females, the difference is not significant (for number of bones and evaluated regions see Table 3).

Fractures of the femur were discovered in both males and females – only one case in each sex: in the female in the region of the neck on the left, and in the male in the region of the diaphysis. A third case, from a pathological aspect the most interesting, was discovered in the material designated as grave admixture.

Similarly, the incidence of tibia fractures was rare – similarly as in the case of fractures of the femur, one case in a male (distal epiphysis) and one case in a female (proximal epiphysis). A third case was also involved (fracture of the diaphysis), discovered in material designated as grave admixture. Fracture of the fibula was recorded in one female in the region of the proximal epiphysis, and in males in a total of 5 cases on the left located on the diaphysis, on the right one located on the proximal end, two fracture of the diaphysis and one fracture in the region of the malleolus (for number of bones and segments see Table 3).

4.2.2 *The most frequent localisation of fractures*

If we compare the frequency of fractures of individual bones (regardless of laterality), the overview above shows that the most frequently represented fractures in the population are those of the clavicle – a total of 12 cases (a total of 480 complete bones were evaluated, including the undetermined individuals and admixtures and including bones calculated by extrapolation). The second most frequent localisation is the forearm – a total of nine fractures of the radius were recorded (of a total 483 complete bones), nine fractures of the ulna (of a total of 418 complete bones). Next in frequency are fractures of the humerus with 7 fractures uncovered (483 complete bones).

The rate of the most frequently uncovered fracture of the clavicle is statistically significantly higher compared to other bones only in the case of the least often affected femur (at the 1% level of significance) and tibia (at the 5% level of significance). The higher frequency of fractures of the clavicle in the evaluated population, though, is not statistically significant even in relation to the frequency of the relatively rare fractures of the pelvic region. The second most frequent localisation of fractures – ulna – is statistically significantly higher compared to femur and tibia (at the 5% level of significance), frequency of fractures of radius is statistically significantly higher in comparison with femur (at the 5% level of significance).

The incidence of fractures of the pectoral girdle and long bones of the upper extremity is significantly higher than the incidence of fractures of the pelvis and the long bones of the lower extremity, at the 1% level of significance. A statistically significant difference remains even if the scapula with low preservation of the area of the angle is not included in the overall comparison in the case of the upper extremity. This significantly decreases the number of complete bones, thus limiting the evaluation.

4.3 **Overview of findings of post-traumatic lesions of the locomotor apparatus**

Grave No 29 – adult individual, undetermined age and sex
healed fracture of the distal half of the left ulna

- (complete preservation of both bones of the forearm (Fig. 3)
- Grave No 39 – male, matusus II (50-60 years)
healed fracture of the clavicle body on the left (distal end not preserved) (Fig. 4)
- Grave No 56 – female, matusus I (40-50 years)
healed fracture of the lateral half of the diaphysis of the left clavicle (clavicles bilaterally preserved, scapula partially evaluable on the left-without traumatic changes)
- Grave No 94 adm. – adult individual, undetermined age and sex; two individuals (admixture)
post-traumatic changes of the acromial end of the clavicle on the right, fusion of the clavicle with the processus acromialis cannot be ruled out, concurrent healed fracture of a rib on the right (Fig. 5)
- Grave No 104 – male, matusus I (40-50 years)
healed fracture of the distal end of the left radius (complete preservation of both bones of the forearm)
- Grave No 114 – female, matusus I (40-50 years)
healed medio-cervical fracture of the femoral neck on the left (femurs bilaterally preserved, pelvis quite incomplete- acetabula cannot be evaluated) (Fig. 6, 7)
- Grave No 126 – female, matusus II (50-60 years)
depressive fracture of the lateral articular surface of the tibia condyle on the left
- Grave No 180 – male, matusus I (40-50 years)
healed fracture of the distal end of the diaphysis of the right radius (the proximal epiphysis of the bone not preserved, only the diaphysis of the ulna available for comparison, the contralateral forearm completely missing)
- Grave No 198 – male, matusus I (40-50 years)
healed fracture of proximal end of diaphysis of the fibula left with inflammatory complications (fibula right and tibia of both sides are well preserved) (Fig. 8)
- Grave No 202 adm. – grave admixture; adult individual, undetermined age and sex,
healed fracture of the diaphysis of the tibia and concurrently of the diaphysis of the fibula on the right
- Grave No 207 adm. – admixture; adult individual, undetermined age and sex
healed fracture of the proximal half of the diaphysis of the left ulna (Fig. 9)
- Grave No 209 – male, matusus II (50-60 years)
healed fracture of the neck of the humerus on the left with subsequent secondary arthrosis and post-traumatic changes to the cavitas glenoidalis of the left scapula with signs of luxation; healed fracture of the distal epiphysis of the radius; healed fracture of the fibular malleolus on the left (skeleton well preserved, with the exception of bilateral damage to the fibula the long bones of the extremities are complete; moreover prior fracture of the sternal end of a rib)
- Grave No 223 – male, matusus II (50-60 years)
healed fracture of the proximal third of diaphysis of the left fibula (from this bone is preserved only its diaphysis; right-side fibula and tibia are not present)
- Grave No 237 – female, adultus II (30-40 years)
healed fracture of the diaphysis of the right ulna (from this bone is missing the distal epiphysis, the left ulna is missing the proximal epiphysis, radius of the right and left side is missing the distal epiphysis)
- Grave No 252 adm. – grave admixture; adult individual, undetermined age and sex
the medio-cervical fracture of the femoral neck healed by pseudo-articulation. (The grave admixture is represented only by this bone) (Fig. 10-12, cf. Fig. 13)
- Grave No 254 – female, matusus I (40-50 years)
healed fracture of the proximal half of the diaphysis of the left radius (the left ulna and bones of the contralateral forearm are complete)
- Grave No 264 – female, matusus II (50-60 years)
healed fracture of the distal half of the diaphysis of the right ulna (completely preserved bones of the forearm bilaterally, with the exception of the distal epiphysis of the fractured ulna on the right) (Fig. 14)
- Grave No 268 – male, matusus I (40-50 years)
healed fracture of the pubic bone on the left (pelvis complete) (Fig. 15)
- Grave No 269 – male, senilis (> 60 years)
healed fracture of the acromial end of the left clavicle, concurrently with post-inflammatory changes (the acromial end of the clavicle on the right not preserved, on the left preserved without damage to the processus acromialis or coracoides) (Fig. 16)
- Grave No 274 – undetermined sex, matusus (40-60 years)
healed old fracture of the distal section of the left radius (the bone is missing the proximal epiphysis, the left ulna is complete, both bones of the forearm on the contralateral side are missing the proximal epiphyses)
- Grave No 276 – male, matusus II (50-60 years)
healed fracture of the diaphysis of the left clavicle, healed fracture of distal third of the diaphysis

- of the left ulna (the right clavicle undamaged, the scapula on the left as well as in the region of the processus coracoideus and acromion without pathology, the right ulna is presented only by diaphysis, right radius is well preserved, the left radius is missing proximal diaphysis) (Fig. 17, 18)
- Grave No 278 – male, senilis (>60 years)
prior fracture of the middle section of the diaphysis of the left fibula (only this diaphysis of the fibula on the left preserved from the among the shin bones)
- Grave No 306 – male, matusus II (50-60 years)
prior fracture of the acromial end of the left clavicle; post-traumatic changes of the medial condyle of the right humerus, which is missing; callus on the medial side of the distal epiphysis of the right tibia; prior bilateral luxation of the sternoclavicular joint (of the long bones of the extremities, only the head of the humerus on the right is missing; of the right radius, only the proximal epiphysis is preserved) (Fig. 19-22)
- Grave No 317 – male, adultus I (20-30 years)
healed fracture of the distal half of the diaphysis of the left radius (both bones of the forearm preserved bilaterally) (Fig. 23)
- Grave No 359 – male, matusus (50-60 years)
healed fracture of the diaphysis of the right radius with dislocation peripherally (the long bones of the extremities completely preserved; myositis ossificans on the linea aspera of the right femur) (Fig. 24-25)
- Grave No 362 – male, matusus I (40-50 years)
healed fracture of the proximal third of the diaphysis of the left humerus (the remaining bones of the upper extremities preserved, without any traumatic changes) (Fig. 26-27)
- Grave No 401 – male, matusus II (50-60 years)
healed fracture of the diaphysis of the left clavicle (the clavicles preserved bilaterally; only the region of the cavitas glenoidalis of the scapulae evaluable) (Fig. 28)
- Grave No 423 – male, matusus I (40-50 years)
healed fracture of the lower rami of the pubic bone bilaterally, these changes are more apparent on the left (on the right, the os ischii is damaged and on the left, the os ilium is damaged) (Fig. 29)
- Grave No 450 – male, matusus I (40-50 years)
post-traumatic changes of the acromion of the right scapula (the scapulas and clavicles preserved undamaged bilaterally)
- Grave No 476 – male, matusus I (40-50 years)
healed fracture of the cavitas glenoidalis region and below the spina scapulae on the right with the formation of a new articular surface ventrally; fracture of the neck and diaphysis of the right humerus with dislocation and a large callus; significant secondary arthritic changes of the humeral head (the long bones of the left upper extremity are missing, only the distal epiphysis of the ulna is missing on the right) (Fig. 30-32)
- Grave No 479 – male, matusus II (50-60 years)
fracture of the distal third of the diaphysis of the left ulna, healed with a pseudo-articulation (both bones of the forearm preserved bilaterally) (Fig. 33)
- Grave No 520/II – adult individual, undeterminable age and sex
healed fracture of the acromial end of the left clavicle (clavicles preserved bilaterally, scapula missing on the left)
- Grave No 604 – male, matusus I (40-50 years)
healed spiral fracture of the middle section of the diaphysis of the left humerus (the bone is missing the proximal epiphysis and the proximal end of the diaphysis); post-traumatic changes on the anterior cavitas glenoidalis of the left scapula (the bones of the left forearm preserved, the right humerus and ulna preserved) (Fig. 34, 35)
- Grave No 617 – male, matusus I (40-50 years)
post-traumatic changes of the left shoulder joint with fusion of the humeral head and the cavitas glenoidalis (the scapula is not well-preserved, the humerus is missing the diaphysis) – in view of the poor state of preservation, the presence of an eventual pseudo-articulation in the region of the humeral neck of cannot be assessed (Fig. 36, cf. Fig. 37)
- Grave No 634 – male, matusus II (50-60 years)
healed fracture of the acromial end of the right clavicle (both clavicles complete, only the cavitas glenoidalis evaluable on the scapulas) (Fig. 38)
- Grave No 640 – male, matusus II (50-60 years)
healed fracture of the proximal end of the left fibula (all the long bones of the lower extremities preserved bilaterally) (Fig. 39)
- Grave No 641 – female, adultus I (20-30 years)
healed fracture of the distal third of the diaphysis of the right ulna (only this diaphysis preserved from the forearm)
- Grave No 657 – male, matusus II (50-60 years)
healed fracture of the distal end of the right clavicle; healed fracture of the diaphysis of the left ulna (the left radius not preserved, both bones of the right forearm preserved)

- Grave No 684 – male, matusus I (40-50 years)
healed fracture of the margo lateralis of the right scapula (association with another possible injury cannot be assessed – only this fragment of the scapula and the diaphysis of the left ulna have been preserved from the bones of the upper extremity; healed fracture of a rib on the left) (Fig. 40)
- Grave No 705 – male, matusus I (40-50 years)
healed fracture of the distal half of the body of the right ulna (only the proximal epiphysis of the radius preserved, the bones of the left forearm complete)
- Grave No 707 – male, matusus I (40-50 years)
healed fracture of the acromial end of the left clavicle with exostosis (possible communication with the dorsal part of the processus coracoideus of the left scapula – this was not preserved though) (Fig. 41)
- Grave No 717 – male, adultus II (30-40 years)
post-traumatic changes of the acromial end of the left clavicle with significant exostosis below and parallel to the processus acromialis of the bone (scapula not preserved, the right scapula and clavicle not preserved either)
- Grave No 769 – male, matusus I (40-50 years)
healed fracture of the distal epiphysis of the right radius (ulna damaged, only the proximal epiphysis preserved, bones of the left forearm complete)
- Grave No 1100 – female, matusus (40-60 years)
healed fracture of the head of the left fibula (shin bones complete, only the head of the right fibula is missing)
- Grave No 1195 – male, matusus I (40-50 years)
healed fracture of the diaphysis of the right femur with significant dislocation longitudinally with contraction and *ad latus et ad axim* (the pelvis bilaterally and the left femur undamaged, tibia preserved, fibulas bilaterally preserved without heads (Fig. 42, 43))
- Grave No 1213 – male, matusus (40-60 years)
healed fracture of the distal end of the left radius and ulna (complete bones of the forearm bilaterally preserved; moreover presence of significant exostosis on the medial side of the distal third of the right femur and inflammatory changes of the periosteum of the distal end of the tibia bilaterally) (Fig. 44)

The sex of individuals was determined by M. STLOUKAL (1967). BRŮŽEK/VELEMÍNSKÝ (2006) and LIKOVSKÝ/VELEMÍNSKÝ/ZIKÁN this book (pp. 223-235), age was estimated by M. STLOUKAL (1967).

5. Discussion

5.1 Population evaluation of the incidence of traumatic changes

5.1.1 Detected frequency of traumatic changes

The population evaluation of the incidence of traumatic changes on the skeleton has been the subject of many studies. These works – with a few exceptions – showed a very low percentage of injuries to individual bones. In contrast to our study, these works mostly did not include in their evaluation the clavicle, scapula and pelvis (for an overview see MANCHESTER/ROBERTS 2007), despite the fact that older publications had already pointed out an increased incidence of fractures of the clavicle (in the case of Mikulčice STLOUKAL/VYHNÁNEK 1976).

As we lack the possibility of comparing our group with another population of the early Middle Ages, the studies dedicated to the prevalence of fractures in the British population of the High Middle Ages are “closest” to our group. With the exception of findings from the leprosarium in Chichester, where involvement of the bones with the lepromatous form of leprosy is presumed to be a factor contributing to the higher incidence of fractures (JUDD/ROBERTS 1998), and with the exception of the conclusions made in older works mapping out fractures on a very small number of bones from the St. Nicolas Shambles cemetery in London (WHITE 1988), the frequency of affected individual bones is very low – fractures of the radius have most frequently reported, although the frequency of this fracture in individual populations ranges from 0.5 to 1.0% (STROUD/KEMP 1993, WIGGINS/BOYLSTON/ROBERTS 1993, GRAUER/ROBERTS 1996; CARDY 1997).

Despite the fact that the aforementioned studies did not focus on the frequency of fractures of the clavicle, scapula and pelvis, fractures of the clavicle are usually considered to be the most frequent in archaeological bone groups. Fractures of the clavicle were more frequently observed in the male population, and their higher incidence on the left was noted at the same time (STLOUKAL/VYHNÁNEK 1976; VYHNÁNEK 1999)

– our observations also correspond to this, but the difference in laterality is not statistically significant.

Another type of injury considered to be the most frequent is the fracture of the diaphysis of the radius and/or ulna, which may occur in self-defence. In our group, the frequency of fractures of the ulna or radius is not significantly higher than that of fractures of other bones. The prevalence of fractures of the radius – 1.87% of all evaluated bones – is nonetheless slightly higher than that determined for the studied British bone groups of the High Middle Ages (see above). Also higher, is the prevalence of fractures of the ulna (2.39% of all evaluated bones) and, surprisingly, the incidence of fractures of the humerus – 1.45%.

It is presumed that the incidence of trauma is affected by the lifestyle and the socio-economic standing of the given population and individuals. The sites evaluated in the area in the area of the Mikulčice castle are considered to be the burial sites of the elite. The grave accessories have also given rise to the assumption that warriors were buried at these sites (e.g. POULÍK 1975). The uncovered traumatic changes, though, take the form of so-called accidental injuries (VYHNÁNEK 1999). Although some of the uncovered injuries could have been caused deliberately (e.g. the fracture of the diaphysis of the humerus due to a massive strike etc.), most of these fractures can be explained by the natural conditions of the locality – this was surrounded by many branches of the Morava river, which in the winter undoubtedly froze over, which certainly represented a higher risk of falls and associated accidental injuries.

5.1.2 State of preservation and method of evaluation

The method of evaluation that we used is a certain modification of the so-called method of five segments (JUDD 2002), devised for the evaluation of fragmented bones. For practical reasons, though, it does not divide the diaphysis into a proximal, medial and distal section. The demarcation of the segments roughly corresponds to the

system of squares (MÜLLER at al. 1990) applying the rules for the ulna and fibula in accordance with JUDD (2002), as it has been shown that for the evaluation of long bones – to increase the total number of complete bones by the extrapolation of individual segments of incomplete bones – the limiting factor is not the preservation and completeness of the diaphysis, but that of the epiphysis.

In our group, it was possible to increase the number of individual long bones by tens using extrapolation. Of the long bones, the least preserved was the fibula, where the preservation of the proximal epiphysis (or the area of the head and neck) was nearly one half compared to the preservation of the diaphysis and the area of the malleolus. The greatest pitfall of population evaluation is presented by the scapula, where most frequently only the area of the lateral angle of the cavitas glenoidalis is preserved. The preservation of the acromial and coracoid processes is only half of that and the preservation of the angle of the scapula and margo lateralis is only one fifth. Despite these restrictions, traumatic lesions were uncovered in both the area of margo lateralis and that of the processus acromialis – this is why we believe it would be a mistake to exclude the evaluation of this bone, or to restrict such evaluation only to the lateral angle, whose preservation approaches that of the other studied bones.

5.2 Individual cases

The long period of time that elapsed between the removal of the material and its initial evaluation as to health status, including fractures, is one of the reasons why the fractures that we discovered do not correspond completely to the published list (STLOUKAL/VYHNÁNEK 1976).

In some cases, one of the problematic issues was the classification of uncovered pathological lesions as “fractures”, although their traumatic origin was highly probable. This, for example, applies to the distinctive exostosis on the inferior side of the acromial end of the clavicle from grave No 693: although, morphologically, it resembles the findings in graves No 707 or 717, we were

unable to prove unequivocally that this was a true fracture of the bone, not even using radiological examinations. In contrast, the shape of the left clavicle of the individual from grave No 276 seemed to point at changes in shape due to bone asymmetry without the presence of a distinctive callus, yet the X-ray uncovered a fracture line.

As to the individual findings of fractures, in a number of cases we found ourselves in a difficult situation, regarding how to classify the findings. This mainly relates to sections of the skeleton or individual bones that were designated as admixture. In graves No 94 or 202, a section of the skeleton of another (prior?) buried individual was designated as an admixture – in such situations we evaluated the “admixture” as an independent individual.

Another „admixture“ involves a group of 8 bones from a total of five graves, of which six are complete. Fractures were uncovered in five cases, other pathologies were found on the remaining bones, for example, advanced degenerative changes. As the studied material mainly originated from the first phase of archaeological research that was conducted in the years 1954-1963 (POLÁČEK 2000) and it was no longer possible to consult the situation of the find with the author of the research (Josef Poulík 1910-1998), the question remains as to how these bones were selected – whether these bones are true grave admixtures, or whether this is a case of directed selection of morphologically altered bones from grave backfills either during removal of the skeletal remains or during laboratory or scientific processing. For example, grave 252 contains as the primary subject of burial a very badly preserved skeleton of a male (of the locomotor apparatus only the diaphyses of the humerus, femurs and tibias are preserved), and as the admixture, in contrast, a very well preserved independent femur with a traumatically separated head, whereby this fracture has healed in the form of a pseudo-articulation. In the original publication (STLOUKAL/VYHNÁNEK 1976), this bone is assigned to the primary subject of the burial – it differs, though, from the other bones. Moreover, as has been said above, both femurs

of the original subject of burial are preserved, even if only in the form of the diaphyses. As this is a case of a relatively rare complication of the healing process of fractures of the femoral neck, we included this finding in the overview – albeit only as an “admixture”.

Another, less usual type of fracture comes from grave No 617. The preservation of the skeleton of the male of *maturus* I age is unfortunately very bad – post-traumatic changes of the left shoulder joint are present, with adhesion of the head, most probably the detached head of the humerus at the level of the neck, to the *cavitas glenoidalis*. In view of the poor state of preservation, we cannot assess the eventual pseudo-joint in the area of the neck of the humerus. Nonetheless, analogues described in clinical literature point to this possibility (HOFFA 1896).

As noted above, most of the findings of fractures can be explained as accidental injuries. In the case of the fractures of the diaphysis of the humerus from graves No 362 and especially No 476, we could speculate that these injuries could have also been caused by a forceful strike to the region of the arm. Isolated fractures of the ulna, including the fracture healed with a pseudo-joint from grave No 479, could have developed in self-defence.

6. Summary

The goal of our study was to verify the frequency of injuries to the bones of the locomotor apparatus in a population group buried on the territory of the castle of the Great Moravian settlement agglomeration at Mikulčice. We purposely chose a burial site, where it is presumed that the elite members of society, including warriors, are buried. We thus focused on burial sites next to the IInd and IIIrd church on the Mikulčice castle, and we based our work on the conclusions of M. STLOUKAL (1963, 1967) in addition to the sections of the necropolis researched later on (POLÁČEK/MAREK 2005).

The method of evaluation is based on that of JUDD (2002), which was devised for the evaluation

of fragmented skeletal material. We simplified the method of five segments: we took the diaphyses of long bones to be a single segment, we also evaluated the bones of the pectoral girdle of the upper extremities and the pelvis. It has been shown that for the evaluation of long bones (and for increasing their total number by the extrapolation of segments of incomplete bones), the limiting factor is not the state of preservation of the diaphyses, but of the region of the epiphyses. The individual segments of bone are clearly defined. This significantly restricts the eventual differences in the manner of evaluation.

From the aspect of the incidence of fractures, the bones of 49 individuals classified in the juvenis group (15-19 years) were evaluated. In this group, no fracture was recorded on the studied bones. Adults represented a total of 531 individuals – a total of 3362 complete bones were examined, with the help of segments this number was increased by a further 452 “complete” bones using extrapolation (total of 3814 bones); a total of 14346 individual segments were evaluated. This number is incremented by additional findings designated as admixtures. In the whole group, a total of 59 fractures was recorded.

There were 42 individuals with fractures – individuals with fractures represented 7.91% of the population. In the group of females (total of 217 individuals), there were 8 fractures recorded – this represented 3.69% of individuals in the population of females. In the group of males (286 individuals), a total of 31 individuals with a total of 43 fractures were uncovered – in several cases multiple injuries were involved. Males with a fracture in this group represented 10.83%. The difference in the frequency of fractures between males and females was significant at the 1% level of significance. The group of adult individuals in whom sex could not be determined represented 28 individuals. In this group, three fractures were recorded in three individuals. Findings designated as admixture represented a group of eight bones – fractures were uncovered in five cases.

If we compare the frequency of fractures of individual bones (regardless of laterality), fractures of the clavicle were most frequent in the group studied – a total of 12 cases. The second most frequent localisation was the forearm. The frequency of fractures of the clavicle was statistically significantly higher compared to the other bones only in the case of the least affected femur (at the 1% level of significance) and tibia (at the 5% level of significance). The prevalence of fractures of the radius was slightly higher than that described in studies focusing on British skeletal groups from the High Middle Ages. Also higher, was the prevalence of fractures of the ulna and humerus. The incidence of fractures of the pectoral girdle and long bones of the upper extremities was significantly higher than that of fractures of the pelvis and long bones of the lower extremities, namely at the 1% level of significance.

The uncovered traumatic changes have, in most cases, the characteristics of so-called accidental pelvic trauma, although it cannot be ruled out that some of the fractures may have been caused deliberately. The overall higher frequency of fractures may be explained, for example, by the natural conditions of the locality – this was surrounded by multiple branches of the Morava river that undoubtedly froze over in the winter, which certainly led to a higher risk of falls and associated accidental injuries.

The help of Doc. RNDr. Milan Stloukal, DrSc. from National Museum, Prague, who yielded very important informations on the population group from the area of the castle in Mikulčice and on particular palaeopathological findings as well, is gratefully acknowledged. For making X-ray pictures are our thanks due to Mr. Marek Jantač.

This research was supported by the projects GAČR 206/03/0725, GAČR 206/07/0699, VZ AV ČR AV0Z80020508 and MSM 0021620843.

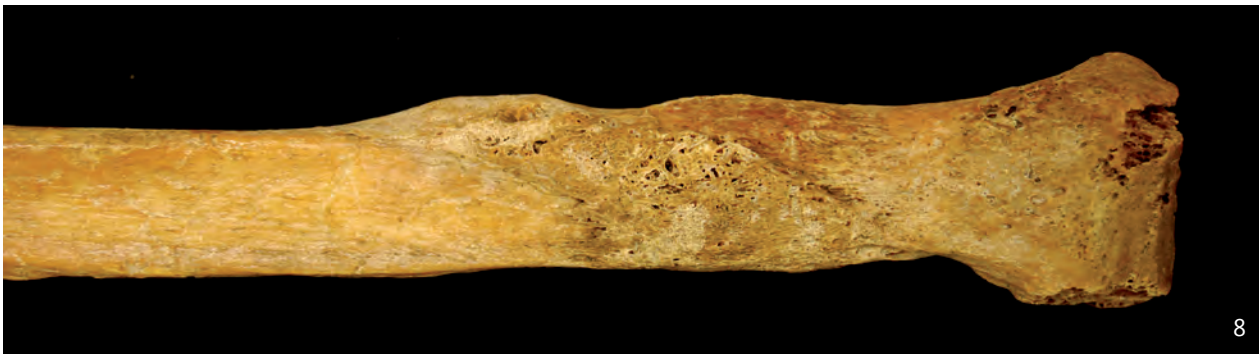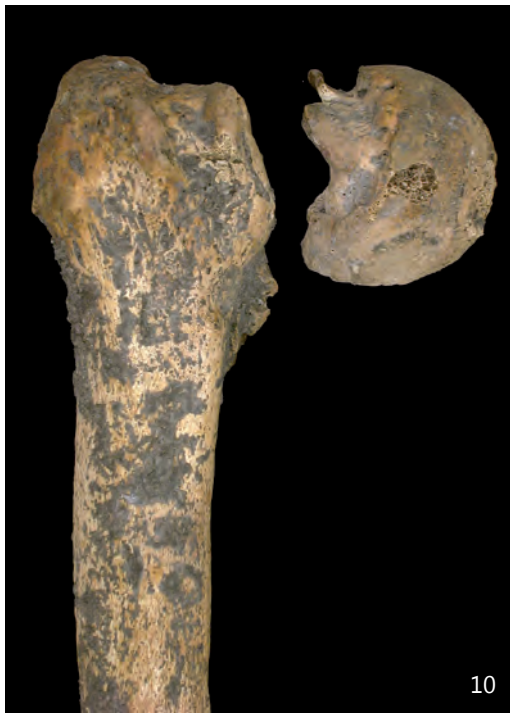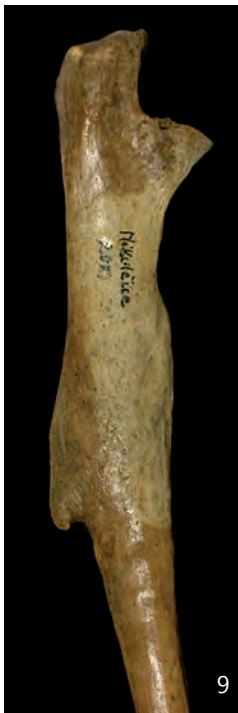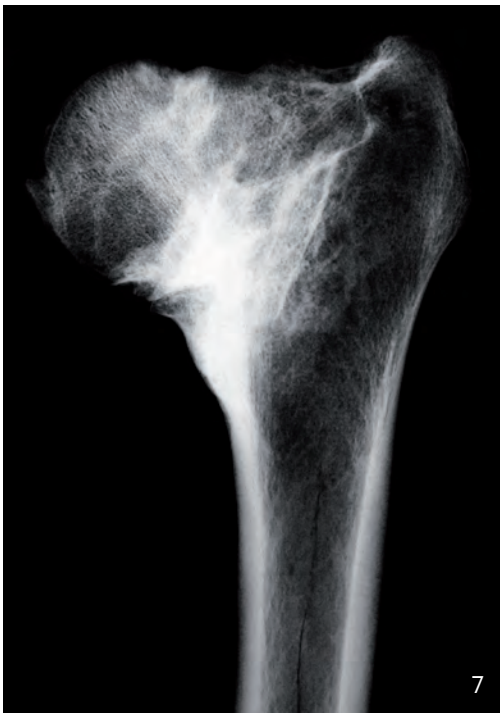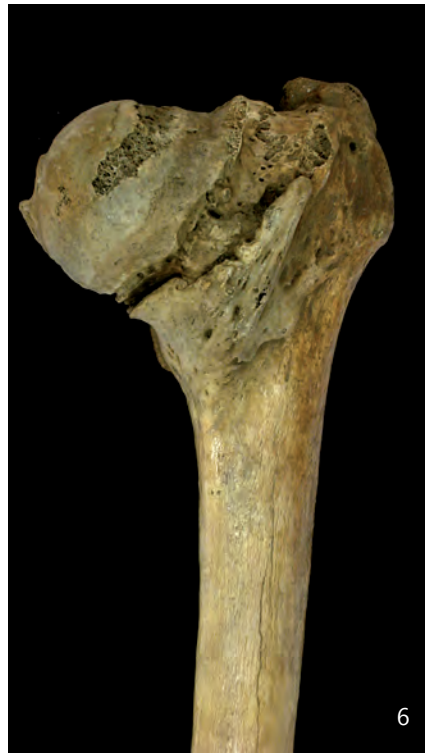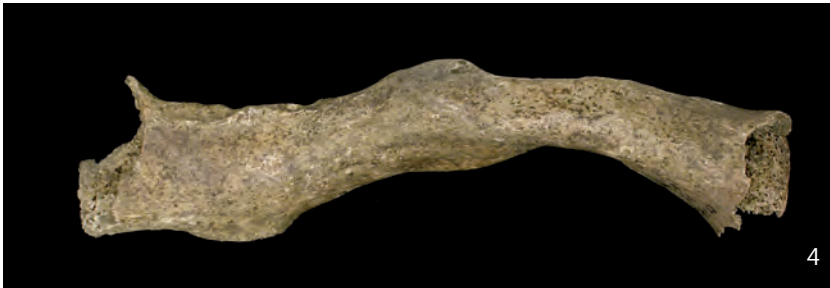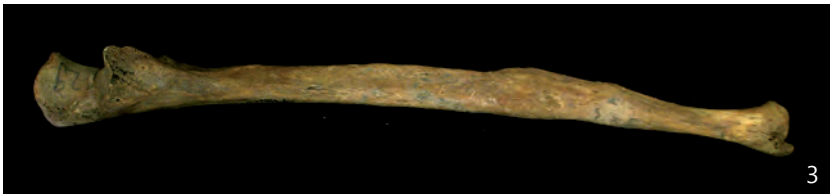References

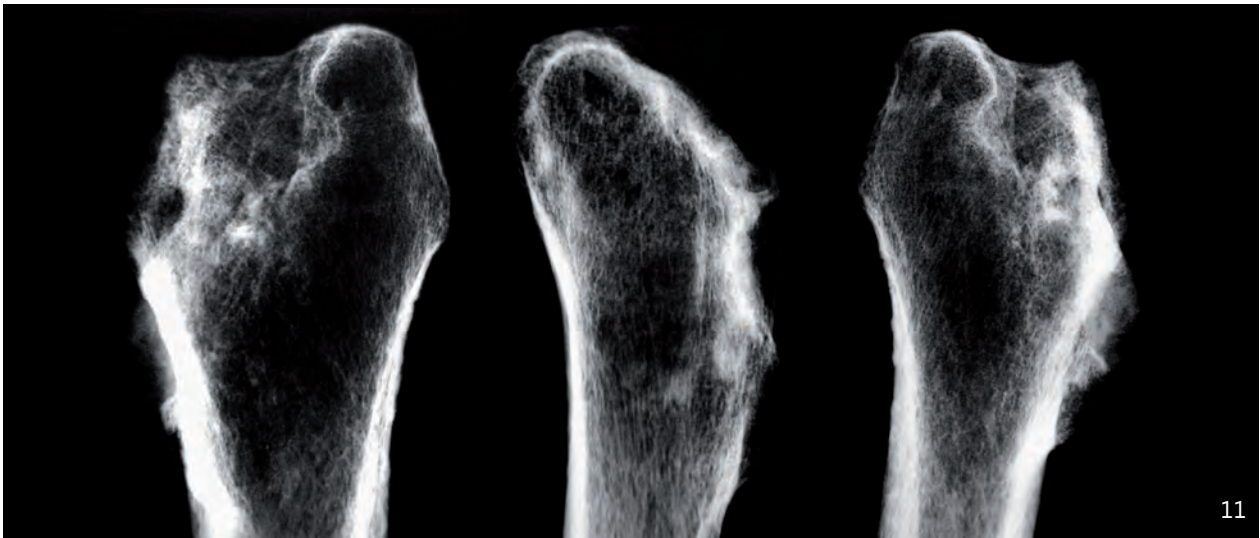
- AUFDERHEIDE/RODRÍGUEZ-MARTÍN 1998 – A.C. Aufderheide/C. Rodríguez-Martín, The Cambridge encyclopedia of human paleopathology (Cambridge University Press, Cambridge 1998).
- BEDNÁŘ et al. 1984 – B. Bednář/D. Benešová/M. Brozman/J. Dobiáš/M. Dluhoš/Č. Dvořáček/M. Elleder/V. Herout/A. Jirásek/R. Kodoušek/Z. Lojda/P. Miřejovský/K. Motlík/Z. Nožička/V. Pazderka/A. Schwarz/J. Stejskal/A. Stejskalová/J. Šlais/I. Šteiner/J. Švejda/J. Tesař/J. Vaněk/M. Vorreith/M. Zavadil, *Patologie (III). II. Systémová patologie* (Avicenum, Praha 1984).
- BRŮŽEK/VELEMÍNSKÝ 2006 – J. Brůžek/P. Velemínský, Sex diagnosis of the early medieval population of Great Moravia (9th to 10th century): proposed population specific discriminant functions for cranial measurements. *Čas. Nár. muz., ř. přírodovědná* 175 (1-2), 2006, 41–56.
- CARDY 1997 – A. Cardy, The environmental material. The human bones. In P. Hill (ed.), *Whithorn and St Niniam: the excavation of a monastic town 1984-91* (Sutton Publishing, Stroud 1997) 519–562.
- DIXON/MASSEY 1969 – W.J. Dixon/F.J. Massey, *Introduction to statistical analysis* (McGraw-Hill, New York 1969).
- GRAUER/ROBERTS 1996 – L.A. Grauer/C.A. Roberts, Paleoepidemiology, healing, and possible treatment of trauma in the medieval cemetery population of St. Helen-on-the-Walls, York, England. *Am. J. Phys. Anthropol.* 100, 1996, 531–544.
- HANÁKOVÁ/VYHNÁNEK 1981 – H. Hanáková/L. Vyhnanek, Paläopathologische Befunde aus dem Gebiet der Tschechoslowakei. *Acta Musei Nationalis Pragae. B, Hist. Naturalis* 37 (1), 1981, 1–76.
- HOFFA 1896 – A. Hoffa, *Fracturen und Luxationen für Ärzte und Studierende* (Werlag und Druck der Stahel'schen k.- und hof und universitätés Buch- und Kunsthandlung, Würzburg 1896).
- HORÁČKOVÁ/STROUHAL/VARGOVÁ 2004 – L. Horáková/E. Strouhal/L. Vargová, *Základy paleopatologie. Panoráma biologické a sociokulturní antropologie*. In: J. Malina (ed.), *Modulové učební texty pro studenty antropologie a „příbuzných“ oborů 15* (Nadace Universitas Masarykiana v Brně, Akademické nakladatelství CERM v Brně, Masarykova univerzita v Brně, Nakladatelství a vydavatelství NAUMA v Brně, Brno 2004).
- JUDD 2002 – M. Judd, Comparison of long bone trauma recording methods. *J. Archaeol. Sci.* 29, 2002, 1255–1265.
- JUDD/ROBERTS 1998 – M. Judd/C.A. Roberts, Fracture patterns at the medieval leper hospital in Chichester. *Am. J. Phys. Anthropol.* 109, 1998, 229–243.
- KOUDELA et al. 2002 – K. Koudela/J. Košťál/J. Matějka/T. Pavelka/M. Toman/I. Topinka, *Ortopedická traumatologie* (Karolinum, Praha 2002).
- LIKOVSKÝ/DRDA 2003 – J. Likovský/P. Drda, Epidurální krvácení na lebce z brány A oppida Závist. *Arch. Rozhledy* 55, 2003, 285–296.
- LIKOVSKÝ/STRÁNSKÁ/VELEMÍNSKÝ 2005 – J. Likovský/P. Stránská/P. Velemínský, An assortment of palaeopathological findings from the anthropological collection of the Institute of Archaeology in Prague in funds of National Museum. *Acta Musei Nationalis Pragae B, Historia Naturalis* 61 (3-4), 2005, 81–140.
- LIKOVSKÝ et al. in print – J. Likovský/P. Velemínský/L. Poláček/J. Velemínská, Zranění pohybového aparátu u velkomoravské populace z mikulčického hradu (Česká republika). In: J. Wrzeński (ed.), *Funeralia Lednickie – spotkanie 10: Epidemie, kleški, wojny* (Poznań in print).
- MANN/MURPHY 1990 – R.V. Mann/S.P. Murphy, *Regional Atlas of Bone Disease* (Ch. C. Thomas, Springfield 1990).
- MAPLES 1986 – W.R. Maples, Trauma analysis by the forensic anthropologist. In: K.J. Reichs (ed.), *Forensic Osteology Advances in the Identification of Human Remains* (Ch. C. Thomas, Springfield 1986) 218–228.
- MÜLLER et al. 1990 – M. Müller/S. Nazarian/P. Koch/J. Schatzker, *The comprehensive classification of fractures of long bones* (Springer-Verlag, New York 1990).
- POKORNÝ et al. 2002 – V. Pokorný/I. Čižmák/P. Havránek/J. Kučera/J. Michek/P. Svoboda/J. Veselý/P. Višňa/J. Vrstýák/P. Wendsche, *Traumatologie* (Triton, Praha 2002).
- POLÁČEK 2000 – L. Poláček, *Terénní výzkum v Mikulčicích. Mikulčice - průvodce 1. Archeologický ústav AV ČR Brno* (Brno 2000).
- POLÁČEK/MAREK 2005 – L. Poláček/O. Marek, *Grundlagen der Topographie des Burgwalls von Mikulčice (Grabungsflächen 1954-1992)*. In: L. Poláček (Hrsg.), *Studien zum Burgwall von Mikulčice VII. Spisy AU AV ČR Brno* 24 (Brno 2005).
- POULÍK 1975 – J. Poulík, *Mikulčice. Sídlo a pevnost knížat velkomoravských* (Academia, Praha 1975).
- ROBERTS/MANCHESTER 2007 – Ch. Roberts/K. Manchester, *The archaeology of disease*. 3rd edition (Cornell University Press, Ithaca, New York 2007).
- STEINBOCK 1976 – R.T. Steinbock, *Paleopathological diagnosis and interpretation* (Ch. C. Thomas, Springfield 2007).
- STLOUKAL 1963 – M. Stloukal, První pohřebiště na hradišti „Valy“ u Mikulčic. *Pam. Arch.* 54, 1963, 114–140.

- STLOUKAL 1967 – M. Stloukal, Druhé pohřebiště na hradišti „Valy“ u Mikulčic. Pam. Arch. 58, 1967, 272–319.
- STLOUKAL/VÝHNÁNEK 1976 – M. Stloukal/L. Vyhnánek, Slované z velkomoravských Mikulčic (Academia, Praha 1976).
- STROUD/KEMP 1993 – G. STROUD/R. KEMP, Cemeteries of St Andrew, Fishergate. The archaeology of York. The medieval cemeteries 12/2. Council for British Archaeology for York Archaeological Trust (York 1993).
- ŠTĚPÁN 1990 – J. Štěpán, Syndrom osteoporózy. Thomayerova sbírka 513 (Avicenum, Praha 1990).
- VELEMÍNSKÝ 2000 – P. Velemínský, Mikulčice – Kostelisko. Projevy nespecifické zátěže a možnosti stanovení pokrevní příbuznosti na základě morfologických znaků. PhD thesis, Faculty of Science, Charles University, Prague (Praha 2000).
- VELEMÍNSKÝ u.a. 2005 – P. Velemínský/J. Likovský/P. Trefný/M. Dobisíková/J. Velemínská/ L. Poláček/H. Hanáková, Großmährisches Gräberfeld auf „Kostelisko“ im Suburbium des Mikulčicer Burgwalls. Demographie, Spuren nicht spezifischer Belastung physiologischen und physischen Charakters auf Skeletten, Gesundheitszustand. In: L. Poláček (Hrsg.), Studien zum Burgwall von Mikulčice VI. Spisy AÚ AV ČR Brno 23 (Brno 2005) 539–633.
- VIŠŇA/HOCH 2004 – P. Višňa/J. Hoch, Traumatologie dospělých (Maxdorf s.r.o., Praha 2004).
- VÝHNÁNEK 1999 – L. Vyhnánek, Nárýs kosterní paleopatologie se zaměřením na radiodiagnostiku. In: M. Stloukal et al. (eds.), Antropologie. Příručka pro studium kostry (Národní muzeum Praha, Praha 1999) 386–432.
- WHITE 1988 – W. White, The cemetery of St. Nicolas Strambles (Museum of London and the London and Middlesex Archaeological Society, London 1988).
- WIGGINS/BOYLSTON/ROBERTS 1993 – R. Wiggins/A. Boylston/C.A. Roberts, Report on the human skeletal remains from Blackfriars, Gloucester (19/91). Unpublished (Ref. by Roberts/Manchester 2007).

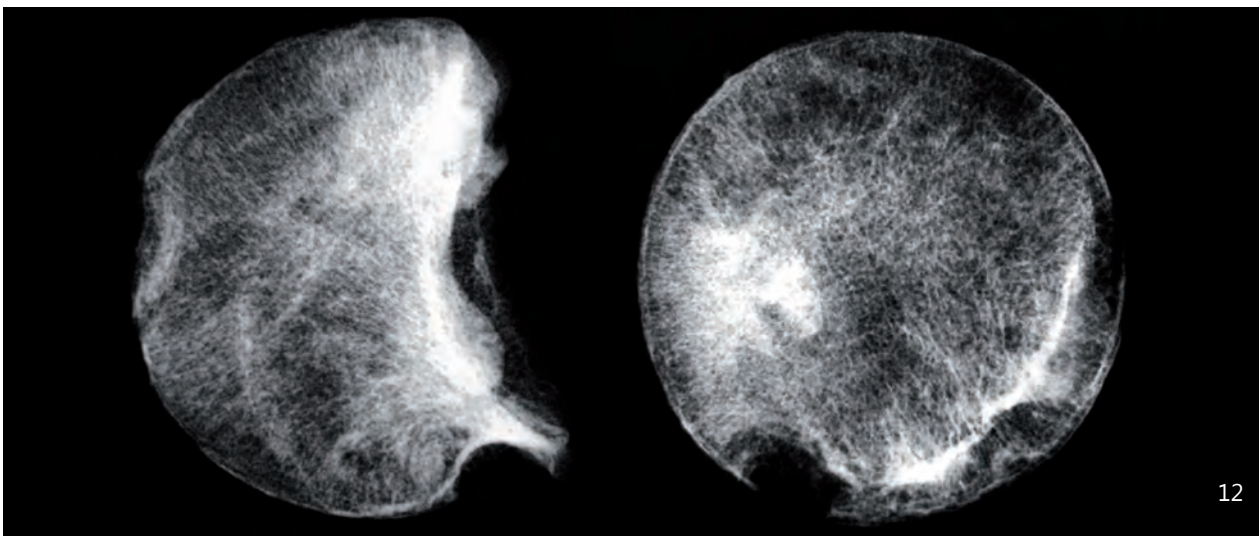
Legends for following pictures

- Fig. 3. Grave No 29. Healed fracture of the distal half left ulnar diaphysis.
- Fig. 4. Grave No 39. Healed fracture of the left clavicle's diaphysis.
- Fig. 5. Grave No 94. Post-traumatic changes of the right clavicle's acromial end.
- Fig. 6. Grave No 114. Healed medio-cervical fracture of the left femoral neck.
- Fig. 7. Grave No 114. Healed medio-cervical fracture of the femoral neck - X-ray picture.
- Fig. 8. Grave No 198. Healed fracture of diaphyseal proximal quarter of the left fibula with inflammatory changes.
- Fig. 9. Grave No 207, admixture. Healed fracture of the proximal half of the left ulnar diaphysis.
- Fig. 10. Grave No 252, admixture. The medio-cervical fracture of the femoral neck healed by the pseudo-articulation.
- Fig. 11. Grave No 252, admixture. Posttraumatic changes of proximal end of femur - X-ray picture.
- Fig. 12. Grave No 252, admixture. X-ray picture of traumatic isolated femoral head.
- Fig. 13. The medio-cervical fracture of the femoral neck healed by the pseudo-articulation exemplified in clinical literature (taken from HOFFA 1996).
- Fig. 14. Grave No 264. Healed fracture of the distal half of the right ulnar diaphysis.
- Fig. 15. Grave No 268. Changes of the symphysis caused by fracture of the left pubic bone.
- Fig. 16. Grave No 269. Healed fracture of the acromial end of the left clavicle.
- Fig. 17. Grave No 276. Healed fracture of the diaphysis of the left clavicle with comparison of the right clavicle.
- Fig. 18. Grave No 276. Healed fracture of the diaphysis of the left clavicle - X-ray picture.
- Fig. 19. Grave No 306. Post-traumatic changes of the acromial end of the left clavicle.
- Fig. 20. Grave No 306. Post-traumatic changes of the medial condyle of the right humerus.
- Fig. 21. Grave No 306. Distal part of the right humerus with post-traumatic changes of the medial condyle.
- Fig. 22. Grave No 306. Distal part of the right humerus with post-traumatic changes of the medial condyle – X-ray picture.
- Fig. 23. Healed fracture of the distal half of the diaphysis of the left radius.
- Fig. 24. Grave No 359. Healed, dislocated fracture of the diaphysis of the right radius.
- Fig. 25. Grave No 359. Healed, dislocated fracture of the diaphysis of the right radius – X-ray picture.
- Fig. 26. Grave No 362. Healed fracture of the proximal third of the diaphysis of the left humerus.
- Fig. 27. Grave No 362. Healed fracture of the proximal third of the diaphysis of the left humerus – X-ray picture.
- Fig. 28. Grave No 401. Healed fracture of the diaphysis of the left clavicle, comparison with the right bone.
- Fig. 29. Grave No 423. Healed, bilateral fracture of the lower rami of the pubic bone – X-ray picture.
- Fig. 30. Grave No 476. Healed fracture of the right humeral diaphysis with dislocation and a large callus.
- Fig. 31. Grave No 476. Neck of the right humerus with secondary arthritic changes of the humeral head.
- Fig. 32. Grave No 476. Healed fracture of the cavitas glenoidalis region and below the spina scapulae on the right.
- Fig. 33. Grave No 479. Fracture of the diaphyseal distal third of the left ulna, healed with the pseudo-articulation.
- Fig. 34. Grave No 604. Post-traumatic changes on the glenoid cavity of the left scapula.
- Fig. 35. Grave No 604. Healed spiral fracture of the diaphyseal middle section of the left humerus.
- Fig. 36. Grave No 617. Post-traumatic changes of the left shoulder joint with fusion of the humeral head and the glenoid cavity.
- Fig. 37. Post-traumatic fusion of the humeral head and the glenoid cavity documented in clinical literature (taken from HOFFA 1996).
- Fig. 38. Grave No 634. Healed fracture of the acromial end of the right clavicle, the comparison with the left clavicle.
- Fig. 39. Grave No 640. Healed fracture of the proximal end of the left fibula.
- Fig. 40. Grave No 684. Healed fracture of the lateral margin of the right scapula – X-ray picture.
- Fig. 41. Grave No 707. Healed fracture of the acromial end of the left clavicle with exostosis, the comparison with the left side.
- Fig. 42. Grave No 1195. Healed, dislocated fracture of the right femoral diaphysis, the comparison with the left side.
- Fig. 43. Grave No 1195. Healed, dislocated fracture of the diaphysis of right femur, posterior view.
- Fig. 44. Grave No 1213. Healed fracture of the distal end of the left radius and ulna.

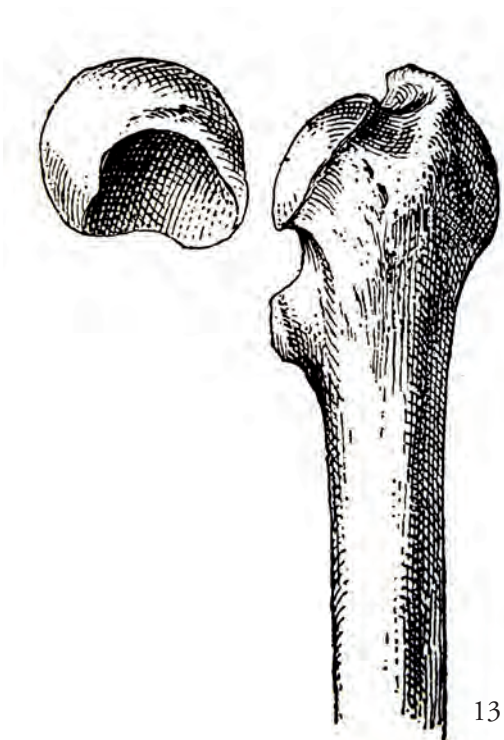




11



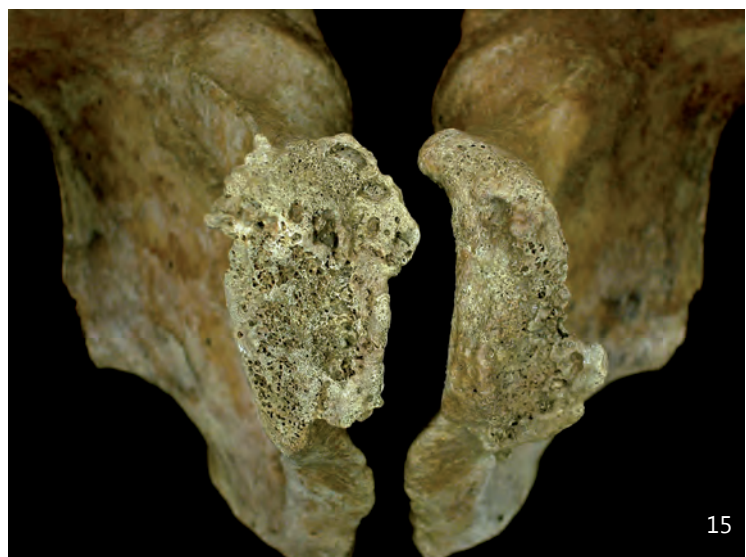
12



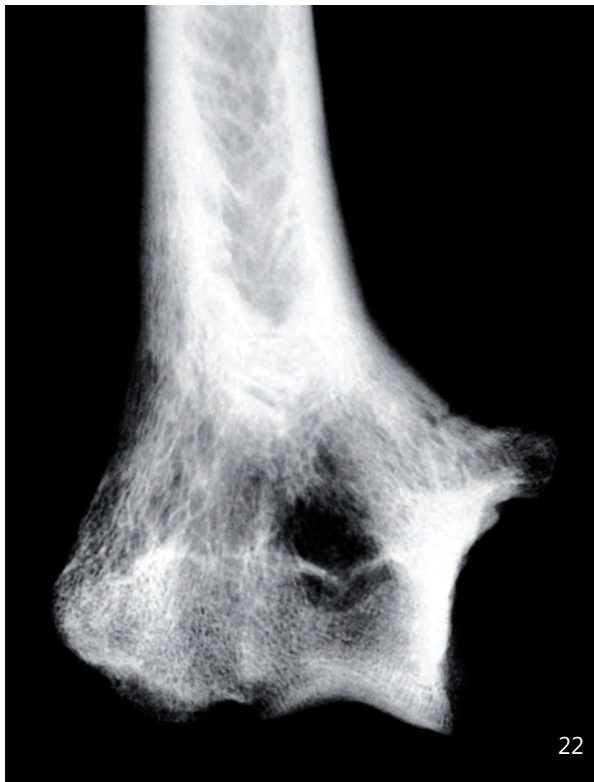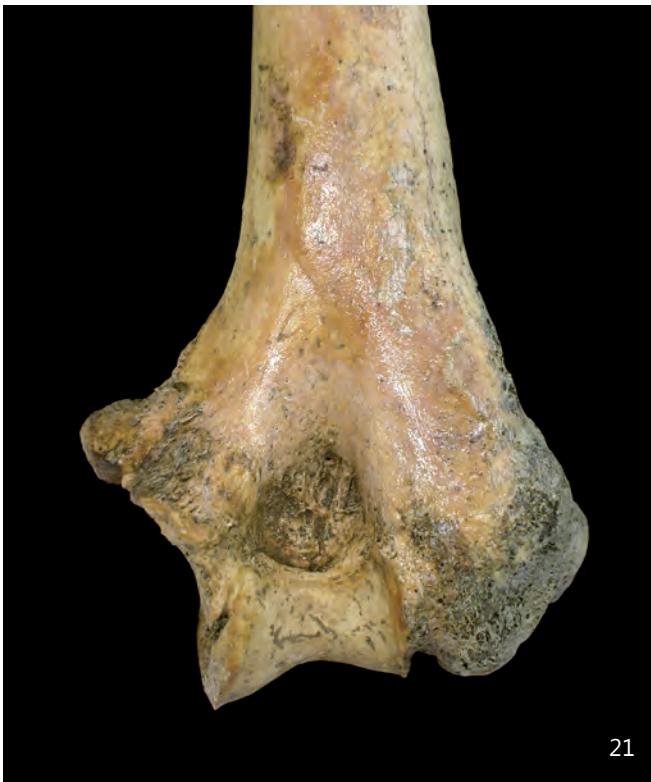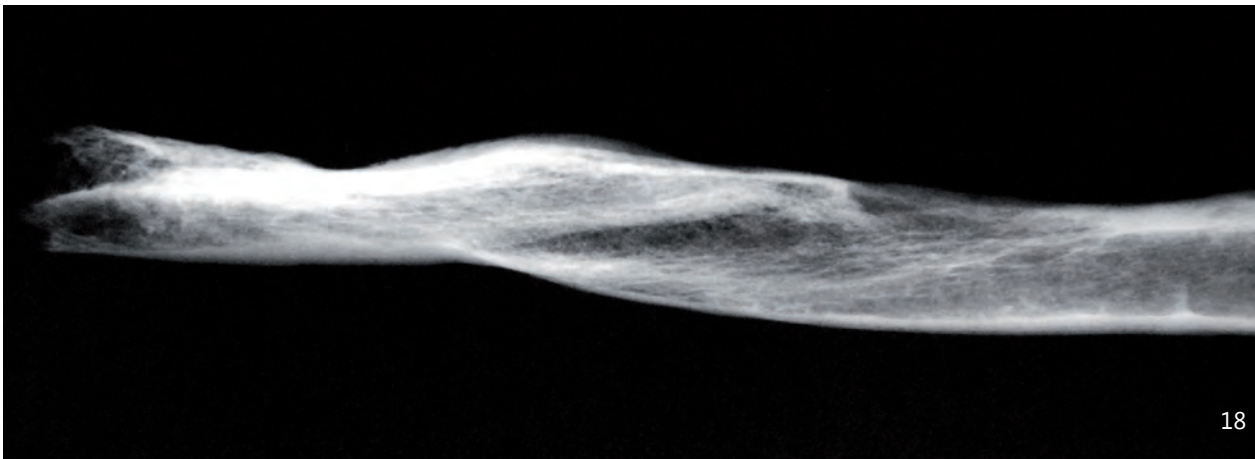
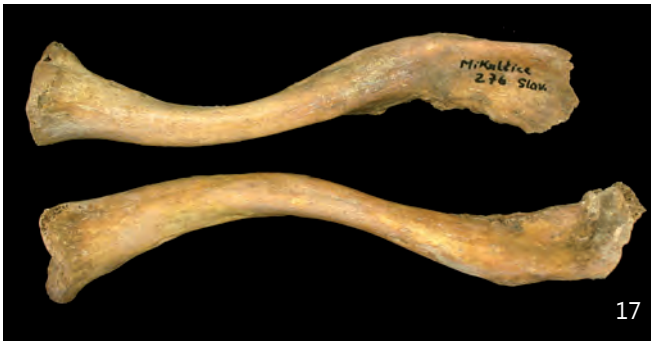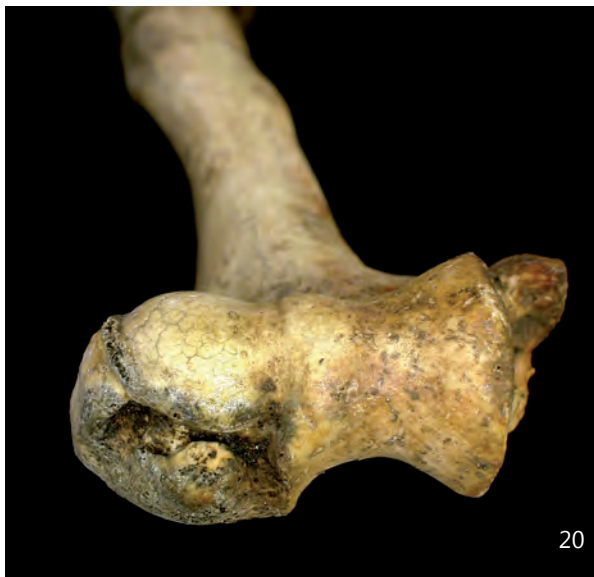13

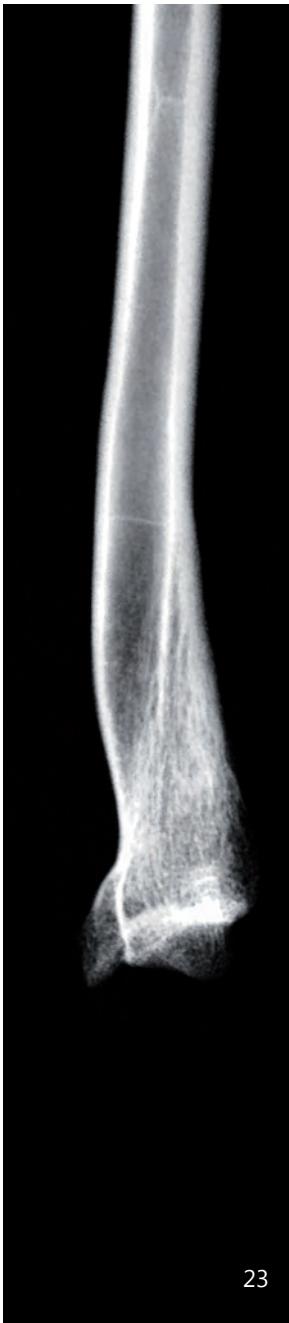

14



15





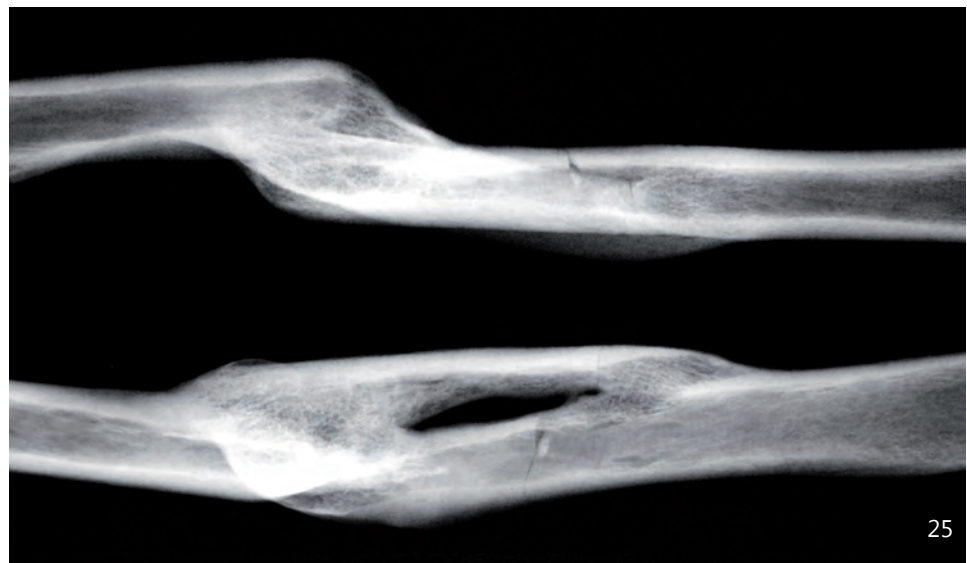
23



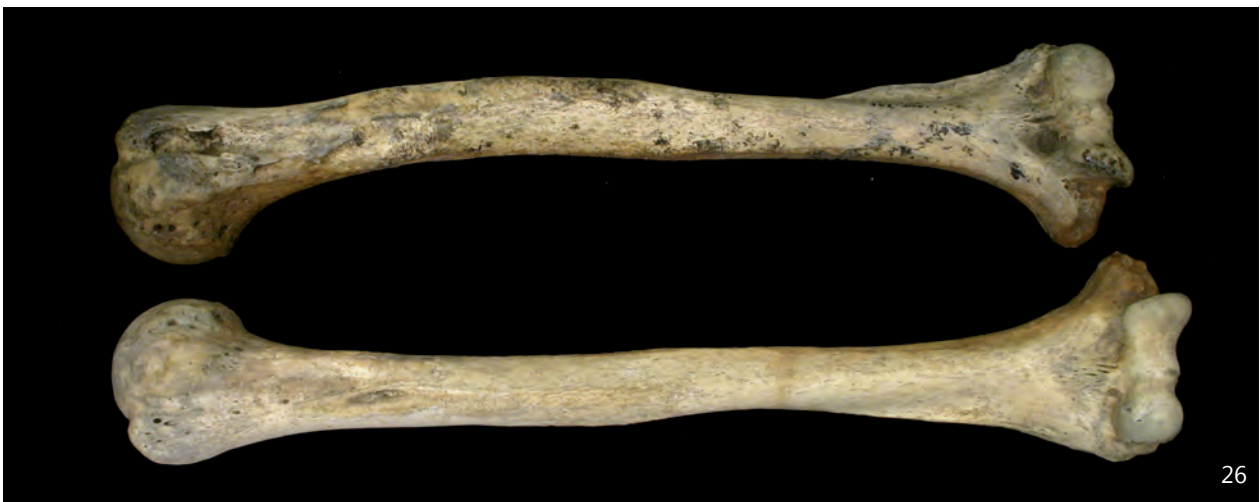19



24



25



26

